



# Presumptive Pregnancy Toxemia and Mesothelioma in a Guinea Pig

Derek Fong<sup>1,2</sup>, Christopher Manuel<sup>1,2</sup>, Patricia Skavlen<sup>1,2</sup>, Justin Laine<sup>1</sup>, Samantha Bozan<sup>1</sup>, Jori Leszczynski<sup>1,2</sup>

Office of Laboratory Animal Resources<sup>1</sup>, Department of Pathology<sup>2</sup>, University of Colorado Denver, Anschutz Medical Campus, Aurora, CO

## Case Report

A 1.07 kg pigmented pregnant (estimated day 20-25 gestation by the vendor) guinea pig of unknown age had a normal physical exam upon arrival. Three days later, she had a decrease in appetite and fecal output with a 0.14 kg (13.1%) weight loss. Physical exam at that time was otherwise normal and 8-10 ml of Critical Care was provided daily as a nutritional supplement. Sixteen days later, she had regained the 0.14 kg lost since arrival, but began to have mild loose stool. A fluid filled structure was palpated in the abdomen, but no fetal structures were palpable, suggestive of fetal demise. Her weight stabilized and Critical Care supplementation was stopped.

Over the next 5 months, mild recurrent loose stool with a few episodes of mild hematochezia were observed and treated with daily hay supplementation. During this time, she also exhibited progressive abdominal distension. Abdominal palpation revealed a fluid consistency with no discrete masses. To determine the cause of abdominal distention, an exploratory surgery was performed, revealing numerous clear and red fluid-filled cysts (0.5 to 5 cm in diameter) arising from the serosal surface of the distal colon and omentum (Figure 1). At one location the omentum was adhered to the colon and appeared to infiltrate the lumen. One uterine horn was thin with a 0.1 x 0.5 cm necrotic focus. Based on the extent of tissue involvement and poor prognosis, the guinea pig was euthanized prior to anesthetic recovery. From histopathology, the top differential diagnosis was a multicystic peritoneal mesothelioma.

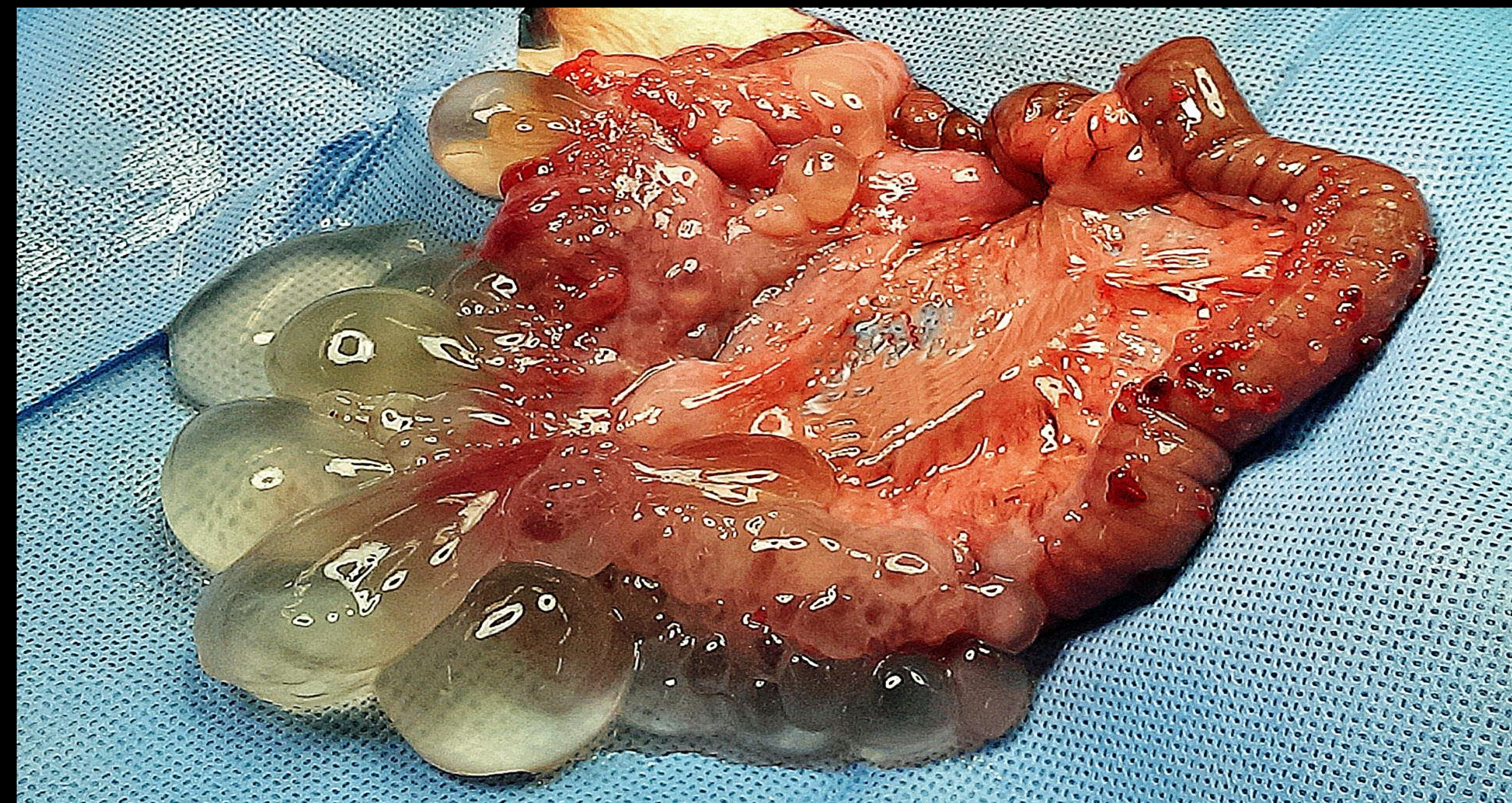


Figure 1 (above): During an exploratory surgery, the affected length of large intestine is removed from the abdomen. Numerous clear to hemorrhagic cysts and nodules line the serosa of the large intestine.



Figure 2 (left): Following euthanasia, the uterus and ovaries were removed. One uterine horn was thin with a brown-black necrotic focus present in the middle of the horn. The necrotic focus is likely remnants from the fetal demise that occurred about 5 months ago.

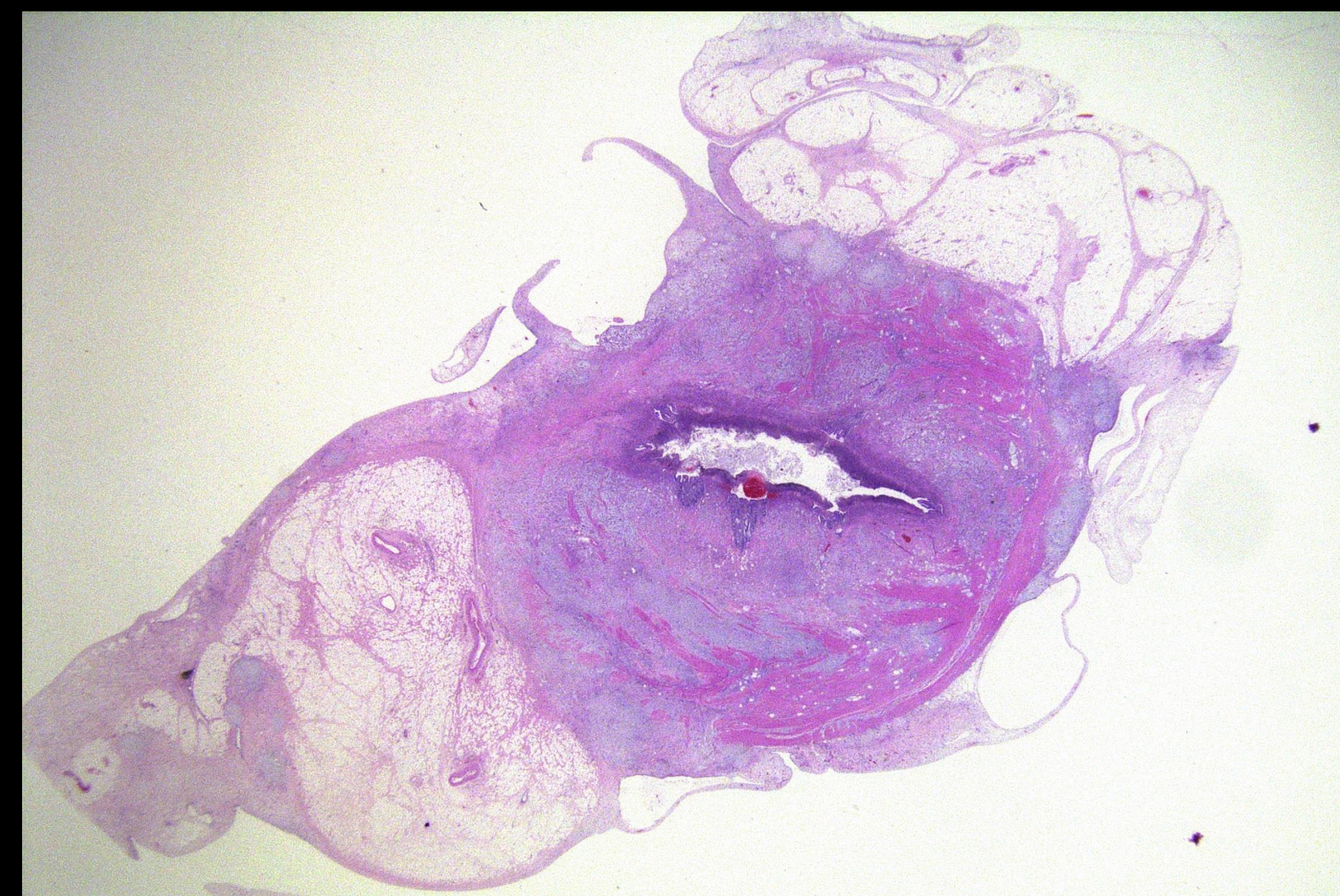

Figure 3 (left): The mass on the colon of this guinea pig was composed of numerous cystic structures, lined by flattened to cuboidal epithelioid cells, embedded in a myxomatous stroma with a fibrovascular core. The same epithelioid cells were also found forming rosettes, small clusters and single cell lined dilated tubules, some with papillary projections, within the myxomatous stroma. The mucosal surface of the colon is ulcerated at the point of tumor invasion into the wall of the colon.

## Discussion

Immunohistochemistry (Vimentin, CD31, pancytokeratin, CEA, Calretinin) performed to definitively diagnosis a mesothelioma was inconclusive. However, mesothelioma is considered the far more likely diagnosis than adenocarcinoma. Mesothelioma has been previously reported in an aged male guinea pig.<sup>1</sup> In this report, hard smooth nodules were found throughout the omentum and abdominal viscera. Mesotheliomas in guinea pigs are rare and not associated with pregnancy toxemia.

We believe this animal underwent fetal demise due to pregnancy toxemia associated with shipping stress. There is not a definitive diagnosis for pregnancy toxemia, but it can be diagnosed based on history and clinical signs, such as anorexia and weight loss. Clinical pathology and histopathology can contribute to the diagnosis also, but were not performed on this animal. Pregnancy toxemia is a known disease in many animals, and guinea pigs are particularly predisposed due to their high stress response. However, in the scientific literature we could find only one publication, reporting a 50% mortality.<sup>2</sup> Similarly, we experienced significant morbidity and mortality of 3 of 6 estimated mid-gestation guinea pigs who were shipped to our facility. There are not efficacious treatments for pregnancy toxemia as only supportive care can be provided and the prognosis is poor. Due to the high rate of morbidity and mortality, we worked with the research group to stop ordering time pregnant guinea pigs and established a successful in-house breeding colony.

## Acknowledgments

We would like to acknowledge Dr. Susan Caraker at Idexx Bioresearch for performing histopathological services. We would also like to acknowledge Raechel Royer, a veterinary technician intern, for photography.

## References

1. Wilson TM and Brigman G. 1982. Abdominal Mesothelioma in an Aged Guinea Pig (*Cavia porcellus*). *Laboratory Animal Science*. 32(2): 175-176.
2. Ganaway JR and Allen AM. 1971. Obesity Predisposes to Pregnancy Toxemia (Ketosis) of Guinea Pigs. *Laboratory Animal Science*. 21(1):40-44.

